

TREATMENT OF PILONIDAL DISEASE USING THE BASCOM "CLEFT LIFT" PROCEDURE

© Steven C. Immerman, MD, FACS

(An abridged version of this manuscript has been accepted for publication in the American Surgeon, 2013)

Background The Cleft-Lift procedure for pilonidal disease, is a procedure that addresses the presence of a deep gluteal cleft as the etiology of the disease.

Methods This study included 84 patients who were treated with the Cleft-Lift procedure between 1993 and 2012. The procedure consisted of excision of the sinus tracts and redundant skin, raising a skin flap, and flattening the gluteal cleft.

Results Eighty eight percent of the patients

healed with no further surgical intervention; 12% required revision of the Cleft-Lift. Patients who had previous failed surgery had a 21% chance of requiring revisional surgery, compared to 8% in patients in their initial presentation. Once primary healing was obtained, there were no late recurrences. The infection rate was 1%.

Conclusions The Cleft-Lift operation is a recommended procedure for treatment of primary and recurrent pilonidal disease.

Introduction

Treating pilonidal disease can be an unrewarding and frustrating experience for a general surgeon. It is not unusual for a busy surgeon to have several young people coming to the office each week for wound evaluations and dressing changes for failed surgical treatment of pilonidal disease, or for treatment of intentionally created open wounds. These patients are uniformly unhappy, and the situation is frustrating and stressful for the patient, the office staff, and the surgeon.

The procedures commonly performed for chronic pilonidal disease are fistulotomy and curettage, marsupialization, excision and primary closure, excision without closure, skin grafting, and skin and rotation flap closures. These procedures all have their benefits and complications, and the selection of the best procedure is controversial. Several of the rotation flap procedures that are categorized as "off midline closures", and include the

Karydakis Procedure and the Cleft-Lift, along with their modifications. This manuscript provides a retrospective review of a series of patients treated with the Cleft-Lift procedure between 1993 and 2012 by a single surgeon in a community setting.

Etiology

The pathogenesis of pilonidal disease was well described by Bascom, indicating an acquired etiology. (1) (2) This has become widely accepted. Bascom expanded on the work of Karydakis (3) and demonstrated that the disease process develops from the presence of a deep gluteal cleft, predisposing to enlarged hair follicles and an anaerobic environment. The follicles distend with keratin and create sinus tracts, which develop into micro abscesses and epithelial tubes. The openings in the skin, coupled with the deep cleft and the pressure phenomenon it creates, allow hairs to migrate into these epithelial tubes and promote acute abscesses and chronic inflammatory disease.

The key points to be taken from the pathophysiology are that the deep cleft predisposes an individual patient to the disease, and that it is a disease of the skin, not the deeper tissues.

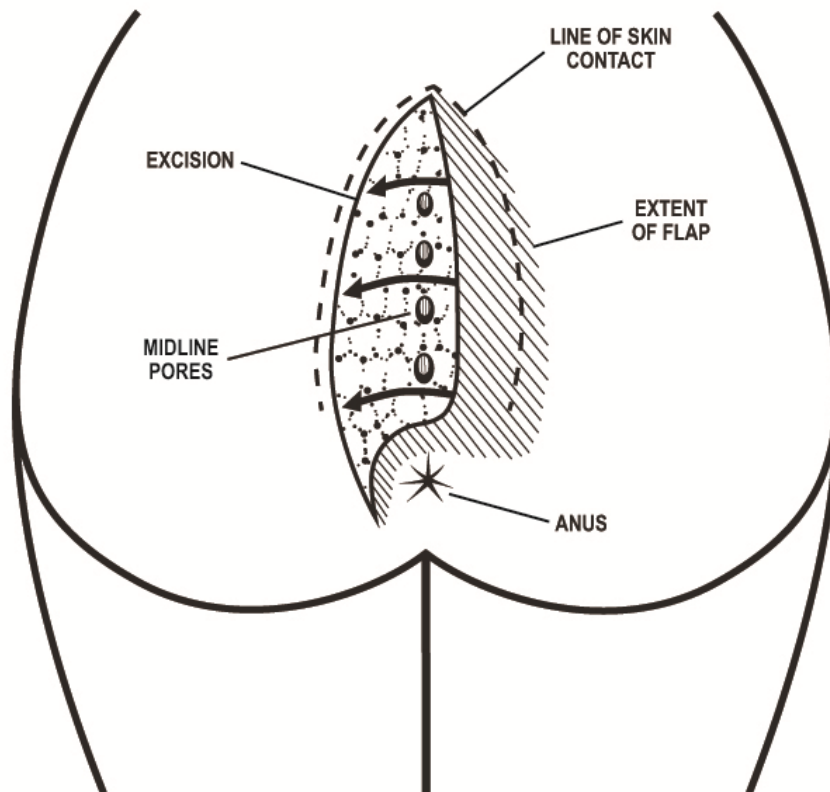
Materials and Methods

This series consist of 84 consecutive patients who were treated with the Cleft-Lift procedure between 1993 and 2012. These were all patients referred to the author with pilonidal

abscess had been drained, these patients were given the options of (1) elective curetting of the abscess cavity and excision of the pits, or (2) the Cleft-Lift procedure. Some patients chose the less extensive procedure. If these patients developed recurrent disease, they had a Cleft-Lift and are included in this series. The technique described by Bascom (4) was used with some minor modifications:

- Oral antibiotics were started on the day

Figure 1: The “off-midline closure” in the modified Bascom Cleft-Lift Procedure



disease by their primary care physician, the emergency room or urgent care clinic, or by self referral. Patients with pilonidal disease who were excluded were those that presented with their first episode of pilonidal disease, associated with a shallow cleft and a minimal number of enlarged pores. Once any acute

before surgery, typically using ciprofloxacin and metronidazole, and were continued for five days post operatively.

- The surgery was done as an outpatient under general anesthesia, with the addition of local infiltration of

bupivacane with epinephrine to decrease postoperative discomfort and minimize intraoperative bleeding.

- With the patients asleep and prone, the buttocks were pressed together and the line of outer skin contact was marked. Figure 1. The buttocks were then taped apart, and the operative area was shaved, painted with povidone-iodine or chlorhexidine, and draped.
- A skin flap was raised on the least diseased side of the gluteal cleft. Inferiorly this flap was then curved over to the diseased side, several centimeters above the anus, just below the area of lowest disease. The flap was raised with a #10 scalpel, using skin hooks for retraction. The flap contained skin, deep dermis, and a small amount of fat, resulting in a flap about a centimeter in thickness. Figure 1.
- The tapes holding the buttocks in place were then released, so that the skin flap could be pulled over to the opposite side to determine the extent of the excision. This was marked, and then the disease process was excised along with the skin on the opposite side of the gluteal fold.
- The excisional portion of the operation was done in such a way that only skin, obvious sinus tracts, and areas of granulation tissue were removed. An attempt was made to remove minimal amounts of fat. All sinus tracts were probed and any debris or granulation tissue was excised or wiped away.
- The wound was irrigated with sodium oxychlorosene antiseptic solution (Chlorpactin™) and drained with a 15 French channel Drain (Blake™) brought out on the upper buttock.
- Closure was done in layers with interrupted 3-0 poliglecaprone 25 (Monocryl™) suture in the deeper layers, and synthetic monofilament (4-0 Biosyn™ or Monocryl™) running

subcuticular suture in the skin. Figure 4. Benzoin and Steri-Strips™ were applied to the portion of the wound superior to the anus.

- The drain was removed on the fifth to seventh postoperative day. There was no specific wound care other than changing dry dressings daily and keeping the drain site dry. Patients were not instructed to perform therapeutic hair removal. No specific restrictions on sitting were given.

Patients were seen in follow up at post op day five to seven, for drain removal and wound evaluation; and again at the third post op week for reevaluation of the wound. At this point, any remaining Steri-Strips™ were removed. Patients were instructed to avoid contact sports until post op week six. No dressings were recommended, and the patient was instructed to keep the operative site clean and dry. If at week three, the wound was healing well and the incision was out of the cleft and off the midline, no further follow up visits were scheduled and the patient was instructed to return for evaluation if any problems developed. If there was any wound separation at week three, the patient was instructed to return at week six for reevaluation. It was at the six week visit where a decision was made regarding reoperation in the patients that required a revision.

In 2012, telephone follow up was attempted on all patients. Patients were queried as to whether they had developed recurrence, or had required any additional treatment for pilonidal disease since they were last examined. In addition, they were asked if they had any residual symptoms or complaints related to the Cleft-Lift.

Results

There were 84 patients treated with the Cleft-Lift over a nineteen year period. The goal of treatment was to obtain a healed wound and to change the configuration of the gluteal cleft so

that the etiology of the disease was eliminated. The success or failure of this procedure is usually evident within one month of the procedure. In 54 (64%) patients, wounds healed primarily without separation or complications. (Table 1). In 20 (24%) patients, there was a

patient with a wound infection who came in for his one-week visit with his dressing unchanged and saturated with stool. There were no other infections or wound seromas. All drains were removed at the first office visit unless the amount of drainage was unusually high, and

Table 1 Results for 84 patients having Cleft Lift Procedure		
Total patients with primary healing, no additional surgery required	74	88%
Immediate healing	54	64%
Slightly delayed healing	20	24%
Required revision of the cleft-lift	10	12%
Patients with primary healing after revision of the cleft-lift*	8	100%
<i>*2 patients requiring revision had successful revision elsewhere.</i>		
Wound Infection	1	1%

slight separation of the skin and deep dermis at the lower third of the incision just above the level of the anus. In these patients the wound healed within a few weeks with no specific wound care or intervention. Thus, primary healing occurred in 74 (88%) of 84 patients. The ten patients who had significant healing problems were taken back to surgery for a revision of the Cleft-Lift. This was done with minimal delay, once it was clear that primary healing would not occur. Revisions consisted of bringing the skin flap farther across the midline, which uniformly resulted in primary healing.

Patients who presented with recurrent disease after other previous operations generally had distortion of the tissues and pilonidal disease closer to the anus. Results comparing patients in whom Cleft-Lift was the primary excisional procedure to those in whom it was a secondary procedure to salvage previous failures are demonstrated in Table 2. Revisions were required in 8% of patients for whom the Cleft-Lift was the primary repair and in 21% of patients for whom the Cleft-Lift procedure was used to salvage a failed prior operation.

Aside from the issues regarding healing, there were few other complications. There was one

there were no situations requiring re-insertion of a drain. Five patients presented on the day of their Cleft-Lift surgery with an unexpected acute abscess. The abscess was drained during the same procedure as the Cleft-Lift operation, and none of these patients developed a wound infection.

An attempt was made to contact all patients in this series to determine late recurrences. Many were of high school or college age at the time of their surgery, so it was not surprising that many were no longer reachable for follow up at this time. However, of the 84 patients in the series, 32 were available for follow-up, with a mean follow up of 5.6 years, a median follow up of 4 years, and a range of 19 years to two months. None had required additional treatment for pilonidal disease. This confirmed our hypothesis, at least for these 32 patients, that once the cleft had been flattened and there was a healed incision off the midline, the disease process had been eradicated.

Although the necessity for a revisional procedure may be viewed as a technical failure of the initial operation, the uniform healing once the incision had been successfully brought off the midline confirmed the validity of the

concept of the Cleft-Lift procedure. The rate of patients requiring a revision of the Cleft-Lift procedure was 9% during the first 15 years of the series and was 7% during the last eight years, suggesting that there was a finite rate of failure with the operation, even with increasing experience.

primary healing in 60% and delayed healing in the remaining 40% of patients, while 5% required further surgery (8), and similar to Bascom (9) who describes a series of 69 patients in which 8.6% required further surgery.

Table 2 Results for 84 patients having Cleft Lift Procedure, stratified by whether the operation was the primary vs. the secondary procedure.		
Cleft-Lift Procedure, primary vs. secondary procedure	Primary N=60	Secondary N=24
Immediate healing	41 (68%)	13 (54%)
Slightly delayed healing	14 (23%)	6 (25%)
Patients with primary healing, no additional surgery required	55 (92%)	19 (79%)
Required revision of cleft-lift	5 (8%)	5 (21%)
Wound Infection	0 (0%)	1 (4%)

Discussion

Pilonidal disease is clearly a difficult problem. Most patients are teenagers or young adults, and dealing with an open, draining, wound is a significant social, physical and psychological problem. The Cleft-Lift was demonstrated to be a successful procedure in the primary and secondary setting. Discussions with these patients made it clear that their goal was not to have a minimal operation, but rather the best possible definitive operation.

Although "off midline closure" procedures, such as the Cleft-Lift and the Karydak's Procedures have been shown to have lower recurrence rates than procedures with midline closures (5) (6), they have not gained popularity among surgeons. It is difficult to ascertain the frequency with which each type of operation is performed, but a 2010 analysis in Denmark showed that more than half the surgeons in public hospitals and 70 percent of surgeons in private hospitals were still performing procedures with midline incisions (7).

Our results were similar to those of Senapati et al., who published a study of 139 patients treated with Cleft-Lift. They demonstrated

Technical

Embarking upon this operation can be daunting for a surgeon unfamiliar with the technical details, and there is a significant learning curve. Although it is simple to envisage a two-dimensional diagram indicating the area of tissue to be removed and the extent of the flap to be mobilized, it is actually more complex because the skin surface of the patient is not two dimensional, but three dimensional as it curves into the gluteal crease. It also changes shape when the patient moves from the prone position to one of standing or sitting; and it changes with time, as the ultimate arrangement of the tissues changes in the weeks immediately after the operation as a new cleft develops, the skin stretches, swelling diminishes, and tissue tension pulls the incision toward the midline.

Issues

Independently adopting this procedure, as opposed to learning this during a surgical residency training program, was difficult but certainly possible. The most serious complication in these 84 patients was poor healing of the wound, which was always clearly attributable to the fact that the flap was not

pulled far enough to the opposite side to flatten the cleft and bring the incision away from the midline. Or, as Karydakis put it, "...the objective of 'no raphe, no wound at depth' had not totally succeeded." (3). This was always remedied by a revision, continuing the rearrangement of tissues that the first operation had not completely accomplished.

It was often difficult to precisely predict where the tissues would fall after the flap was raised and the skin was excised. The general concepts that are helpful are: 1) skin removal needs to be aggressive; and 2) the surgeon needs to constantly re-evaluate the amount and configuration of skin removed during the procedure and modify as needed. A useful maneuver was to complete the closure, but before the patient was moved off the table, to apply bilateral medial pressure on the buttocks to see how the tissues were reshaped. If this demonstrated that a new cleft had formed and that the incision fell in this cleft, additional skin was resected as needed until the cleft was flattened and the incision was off the midline and out of the cleft.

The thickness of the flap is somewhat controversial. While Bascom describes a very thin flap containing only skin and deep dermis, we used a thicker flap, similar to the one described by Theodoropoulos et al (10) which provides a more viable, robust, flap.

It was also important to place numerous deep sutures to bring the subcutaneous tissue on the flap side, across the midline. These sutures alleviated some of the tension on the skin incision and prevented it from migrating back toward the midline. Nonetheless, despite careful surgical methodology and many years of experience with this procedure, revisions were still necessary.

The incidence of postoperative wound infection in these contaminated incisions close to the anus was remarkably low (1%). The interventions used to prevent infection included starting antibiotics the day before surgery,

irrigating the wound with antiseptic solution during the procedure, placing a closed-suction drain into the deep subcutaneous tissue, and continuing antibiotics for five days after surgery. It is possible these interventions were unnecessary, but in aggregate they were successful in keeping the infection rate low. Although performing a Cleft-Lift procedure in a patient with an active abscess is not preferred, the lack of infections in the five patients who had this procedure performed in the presence of a concomitant acute abscess suggests that it is not contraindicated.

Dealing with poor healing and recurrence

Patients were seen five to seven days after the procedure in order to remove their drain, and then again about two weeks later. It would be at the second visit when any wound separation would usually become evident. If the location of the wound and the appearance of the cleft appeared optimal, the separation could be from tension on the wound, or from trauma to the area. In those cases wounds healed in a few weeks. If the separated area was still buried within a newly formed cleft, it most likely would not heal. If it was clear that the separation was becoming deeper or showed characteristic signs of recurrent pilonidal disease at six weeks postoperative, the patient was returned to the operating room for a revision of the Cleft-Lift with as little delay as possible. The decision to reoperate rather than attempt to obtain healing with prolonged wound care was a judgment of the surgeon, in keeping with the goal of avoiding subjecting these young patients to months of frustrating wound care. Therefore, none of the patients in this series were left with open wounds once it was clear that they had recurrent disease, nor were any patients treated with hair removal, packing, Monsel's or Dakin's solution, or a Wound-V.A.C.

Conclusions

The Cleft-Lift procedure as described by Bascom was an excellent operation for treatment of pilonidal disease, both as a primary operation in patients with evidence of disease and a deep

gluteal cleft, and for patients with previous, failed excisional procedures. Although obtaining a uniformly successful result was an elusive goal, it was possible for a community surgeon to learn this procedure. Since it did not require any specialized, expensive equipment and did not have frequent significant complications, the operation was much more appealing than excision with open packing. It should be part of the surgeon's armamentarium when treating pilonidal disease.

Bibliography

1. *Pilonidal Disease: Origin from follicles of hairs and results fo follicle removal as treatment.* **J, Bascom.** 1980, Surgery, pp. 567-572.

2. *Pilonidal Diease: Correcting Overtreatment and Undertreatment.* **J, Bascom.** 1981, Contemporary Surgery, pp. 13-28.

3. *Easy and Successful Treatment of Pilonidal Sinus after explanation of it's Causative Process.* **G, Karydakis.** 1992, The Australian and New Zealand Journal of Surgery, pp. 385-389.

4. **J, Bascom.** Pilonidal Sinus. Toronto : Decker, 1990, pp. 32-39.

5. *Management of 634 Consecutive Patients with Chronic Pilonidal Sinus: A Nine-Year Experience of a Single Institute.* **Sakr, MF, et al.** 2012, Surgical Science, pp. 145-154.

6. *Pilonidal sinus: has off-midline closure become the gold standard?* **Kitchen, P.** 1979, ANZ J Surg, pp. 4-9.

7. *Treatment of Pilonidal Sinuses in Denmark is Not Optimal.* **Fabricus, R, Peterson, LW and Bertelsen, CA.** 2010, Danish Medical Bulletin, pp. 1-5.

8. *Cleft closure for the treatment of pilonidal sinus disease.* **Senapati, NP, et al.** s.l. :

Colorectal Disease, 2011, Colorectal Disease, Vol. 13, pp. 333-336.

9. *Failed Pilonidal Surgery: New Paradigm and New Operation Leading to Cures.* **Bascom, J and Bascom, T.** 2002, Archives of Surgery, pp. 1146-1150.

10. *Modified Bascom's Asymmetric Midgluteal Cleft Closure Technique for Recurrent Pilonidal Disease.* **Theodoropoulous, G, et al.** 9, Athens, Greece : Dis Colon Rectum, 2003, Vol. 46.

11. *Pilonidal Disease.* **Hull, T and Wu, J.** 2002 йил, Surg Clin N. Am, pp. 1169-1185.